Cureus
Part of SPRINGER NATURE

Open Access Case Report

Eighty-Year-Old Male With Normal Pressure Hydrocephalus Presenting With Dementia and Parkinsonism Treated Using Electroencephalography (EEG)-Guided H4 Coil Protocol: A Case Report

Aswin Kumar Mudunuru [1], Kartik Valipay [2], Arifa Rahman [3], Sailaja Bomma [4], Lalitha V. Jahnavi [4], M. S. Reddy [5]

1. Non-Invasive Brain Stimulation, Asha Neuromodulation Clinics, Hyderabad, IND 2. Psychiatry, Asha Neuromodulation Clinics, Hyderabad, IND 3. Neurology, Asha Neuromodulation Clinics, Hyderabad, IND 4. Psychology, Asha Neuromodulation Clinics, Hyderabad, IND 5. Psychiatry, Asha Hospital, Hyderabad, IND

Corresponding author: Aswin Kumar Mudunuru, akartik1985@gmail.com

Review began 07/17/2025
Review ended 07/30/2025
Published 07/31/2025

© Copyright 2025
Mudunuru et al. This is an open access article distributed under the terms of the Creative Commons Attribution License CC-BY 4.0., which permits unrestricted use, distribution, and reproduction in any medium, provided the original author and source are credited.

DOI: 10.7759/cureus.89177

Abstract

Idiopathic Normal Pressure Hydrocephalus (iNPH) is a rare syndrome of apractic or ataxic gait, mild to moderate dementia, and urinary incontinence. The cerebrospinal fluid tap test is widely used in the diagnosis of NPH. Using deep Transcranial Magnetic Simulation (DTMS) with H coils, we developed a novel treatment method that incorporates electroencephalography (EEG)-based customization of the treatment protocol. An 80-year-old male presented with clinical signs of slowness of gait and activity, rigidity, and urinary incontinence, which progressed to bradykinesia, magnetic, short, and shuffling gait. He later developed altered behavior, memory loss, and cognitive deficit. Administration of 17 DTMS sessions with an H4 coil provided transient relief from a few symptoms for approximately two months. Fast Fourier transform analysis of the frontal EEG was used to find the peak activity and customize the treatment protocol. Eleven DTMS sessions with optimized protocol gave a sustainable symptomatic relief as well as improved functionality, as estimated on 10-month follow-up.

Categories: Neurology, Psychiatry, Other
Keywords: deep tms, eeg, h4 coil, idiopathic nph, parkinson's disease dementia

Introduction

Idiopathic Normal Pressure Hydrocephalus (iNPH) is a rare syndrome characterized by apractic or ataxic gait, mild to moderate dementia, and urinary incontinence, presumed to be caused by obstruction to normal flow of cerebrospinal fluid (CSF) and delayed absorption into the venous system, resulting in enlarged ventricles with relatively less increase in CSF pressure [1,2]. Both sexes are affected by the disease [3]. Characteristic imaging findings include communicating hydrocephalus with a patent aqueduct of Sylvius, without cortical or hippocampal atrophy, usually. Although there is no specific diagnostic method, the CSF tap test (CTT) is widely used in the diagnosis of iNPH [4]. The surgical treatment for iNPH involving implantation of a ventriculoperitoneal shunt (VPS) results in a favorable outcome in approximately 30%-50% of patients [5-7]. Subdural hematoma (SDH) and infection are common surgical complications [8]. A transient improvement in gait and cognitive function has also been observed following lumbar puncture (LP) with removal of >30 mL of CSF [9]. However, no treatment consistently yields predictable results across all patients, highlighting the importance of exploring alternative approaches. The non-invasive brain stimulation technique of transcranial magnetic stimulation (TMS) has shown value in diagnostic evaluation of iNPH, including as a predictor of shunt response [10]. However, it has not been used as a treatment. In this case report, we investigate the use of an optimized form of the stimulation technology known as deep TMS (DTMS) for the treatment of iNPH using EEG-based customization. This customization involves replacing the treatment frequency with extracted peak frequencies from the Fast Fourier Transform (FFT) graphs, as reported previously [11].

Case Presentation

Patient RK, a 77-year-old male, had a head injury due to an accidental fall in April 2020. CT scan showed SDH of approximately 4 mm thickness in the right fronto-parieto-temporal convexity. He developed slowness of gait and activity, difficulty in getting up from sitting posture, and urinary incontinence, which worsened over time. Five months later, a repeat CT revealed diffuse cerebral atrophy with small vessel ischemia, with no evidence of right-sided SDH. Over the next few months, symptoms worsened with the development of bradykinesia, magnetic, short, and shuffling gait, rigidity on the left side, and significant postural instability. In February 2021, there was decreased interest in activity, altered behavior, memory loss, and cognitive deficit. The diagnosis of atypical Parkinsonism was made at this time. Movement Disorder Society Unified Parkinson's Disease Rating Scale (MDS-UPDRSIII) motor scoring was 80/132 [12].

How to cite this article
Mudunuru A, Valipay K, Rahman A, et al. (July 31, 2025) Eighty-Year-Old Male With Normal Pressure Hydrocephalus Presenting With Dementia and Parkinsonism Treated Using Electroencephalography (EEG)-Guided H4 Coil Protocol: A Case Report. Cureus 17(7): e89177. DOI 10.7759/cureus.89177

The patient was started on Syndopa 125 mg once a day. After five months, as the symptoms were not getting controlled, the possibility of iNPH was suspected, and a CSF tap was done. Gait improved within 24 hours after the first CSF tap. Two months later, the rigidity and behavioral changes reappeared with additional findings such as backward falls during attempted walking, proximal muscle weakness, proprioceptive anesthesia, reduced arm swing, memory loss, and inability to adjust to newer environments. The patient underwent periodical CSF taps about six to eight months apart, only to witness transient improvement in all the symptoms. The family members consulted our Neuromodulation Clinic during January 2024 (aged 81 years) for the complaints of depressed mood, memory loss, and cognitive deficit. During the consultation, the previous diagnosis of iNPH was uncovered by our psychiatrist.

Examination findings

At presentation, the patient was on Syndopa 125 mg and other conventional medications with standard daily dosages for hypertension (Telmisartan 40 mg), hypercholesterolemia (Atorvastatin 20 mg), diabetes mellitus (Glimepiride and Metformin 1+500 mg), and hypothyroidism (Levothyroxine 50 µg). There was no significant finding in all other routine lab tests. The Mental Status Examination revealed tangential speech, normal eye contact, flat affect, depressed mood, distracted attention, and no hallucinations, suicidality, or delusions. He had mild depression recorded on the Hamilton Depression Rating Scale-21 (HDRS-21) as 10 points [13]. The Mini-Mental State Examination (MMSE) score was 14, and the Montreal Cognitive Assessment (MoCA) score was 12, indicating moderate cognitive impairment [14,15]. Neurological examination revealed 4/5 to 5/5 power in major muscle groups in all four limbs, marked rigidity on the left side of the body, proprioceptive anesthesia, micrographia, step length 0.4 feet (10/25), and stride length 0.8 feet (10/12.5) (measured as distance in feet/no. of steps or strides). MDS-UPDRSIII Motor Scoring was 94/132, indicating severe impairment.

First treatment plan

All the drugs were maintained status quo during DTMS treatment. Screening for electromagnetic field compatibility was done before DTMS. H4 coil was used to apply BrainsWay's evidence-based protocol for the treatment of Parkinson's disease [16,17]. In January 2024, 17 consecutive sessions of DTMS were given once daily, each lasting for about 30 minutes. Each session consisted of one low-frequency stimulation (LFS) of 1 Hz over the bilateral motor cortex (M1) given at 90% of resting motor threshold (RMT) with up to 900-1,400 pulses. This was followed by a high-frequency stimulation (HFS) of 10 Hz over the bilateral prefrontal cortex (PFC) given at 100% of RMT up to 800-1,200 pulses. Following this, six more maintenance sessions were given on alternate days in February 2024. The patient gained good control of urinary incontinence and a partial reduction in the rigidity. He was able to walk with support, especially after rising from sleep or in the early hours of the day. Step length was 0.5 feet (10/20) and stride length was 1 foot (10/10). However, there was no noticeable improvement in cognitive abilities and memory. In April 2024, the patient exhibited a minor worsening of his symptoms and was taken for CSF tapping. The neurologist noticed that the CSF pressure and volume were lower than before, and the immediate improvement, which was usually seen after the tapping, did not appear this time. He was brought back to the Neuromodulation Clinic during the last week of April to repeat the DTMS treatment.

Due to the limited improvement achieved thus far with DTMS treatment, it was decided to optimize the protocol by customizing it to match the patient's cortical electrical activity. For this purpose, a 32-channel EEG was acquired (NeuroMax NMX 32) using a standard procedure [18]. FFT analysis measuring Power Spectral Density against the frequency using the Hamming window algorithm was subsequently used to extract an average peak frequency of 1.6 Hz over the frontal areas (Figure *1*) and 0.9 Hz over the bilateral M1 (Figure *2*).

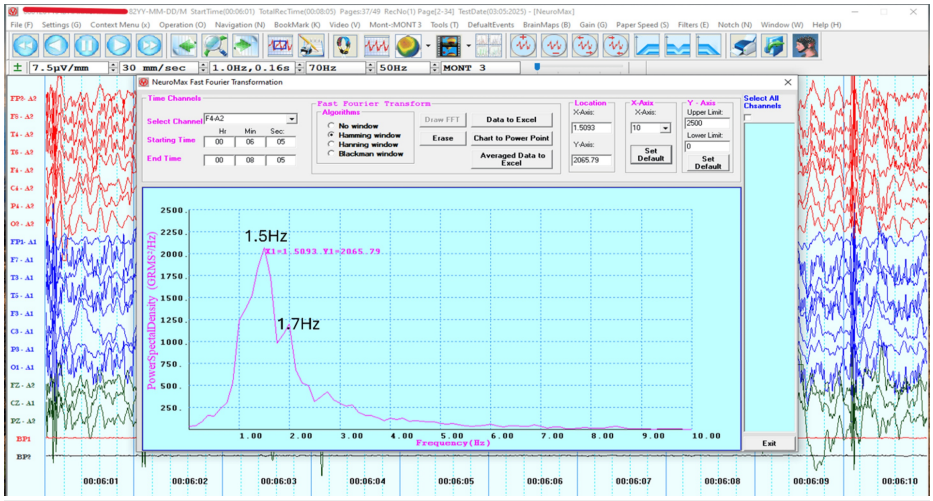

FIGURE 1: Fast Fourier Transform (FFT) graph from the F4-A2 electroencephalography (EEG) montage.

The peak frequencies at 1.5 and 1.7 Hz are seen in the FFT graph of the F4-A2 montage.

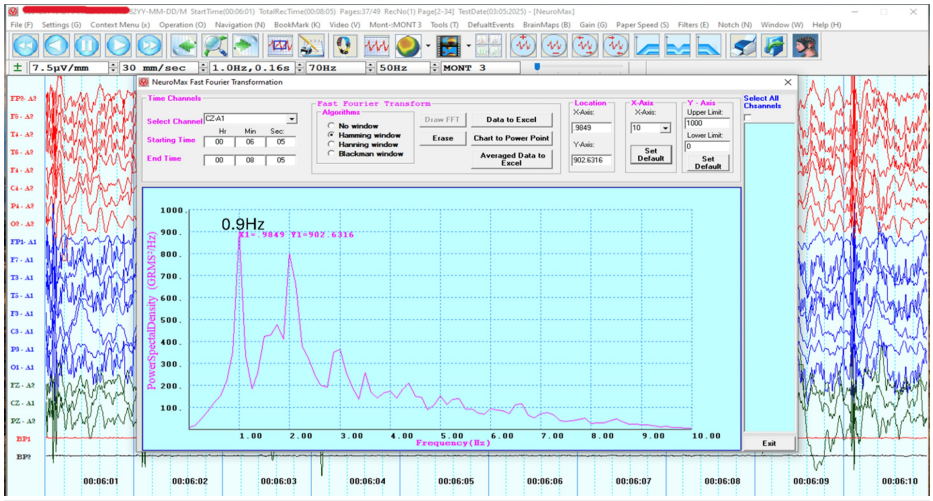

FIGURE 2: Fast Fourier Transform (FFT) graph from the Cz-A1 electroencephalography (EEG) montage.

The peak frequencies at 0.9 Hz are seen in the FFT graph of the Cz-A1 montage.

Second treatment plan

After the routine screening for TMS compatibility and informed consent, the second plan was started. The new optimized treatment protocol consisted of three parts per single session, each complete session lasting for about 45 minutes:

(1) H4 coil: LFS with 1.6 Hz over bilateral PFC given at 120% of RMT of the right hand, delivering about 1,980 pulses, i.e., 62 trains of 1.6 Hz and 20 seconds duration with 5 seconds interval.

(2) H4 coil: LFS with 0.9 Hz over bilateral M1 given at 90% of RMT of the right hand, delivering about 1,200 pulses, i.e., 75 trains of 0.8 Hz and 20 seconds duration with 1 second interval.

(3) H7 coil: HFS with 10 Hz over the medial motor cortex given at 100% of RMT of the right foot, delivering about 800-1,200 pulses. This stimulation was assumed to affect the cortical control areas for bladder activity.

This composite treatment session was applied once daily for seven days, followed by four sessions given once every two days. At the end of this 15-day composite treatment, there was marked improvement in the gait

and cognition in the patient. After the sixth treatment day, he was observed to be reading a book for about an hour, which he had not done for about five years. The MDS-UPDRS Part III, MMSE, and MoCA scores were 37/132, 22, and 24, respectively, indicating moderate motor impairment and mild cognitive impairment. The patient's step length was 0.83 feet (10/12 ft), and the stride length was 1.66 feet (10/6 ft).

There was no change in the medication after the second treatment plan. In a review consultation that took place four days after the last treatment, improved urinary continence, marked cognitive improvement, and moderately improved gait were reported. Three months after the end of the treatment, the patient arrived having walked to the clinic unsupported. He was active, able to recollect the memories from his past as old as from 1970s. After about one year, nine more DTMS sessions, same as the second treatment plan, were given as maintenance, once daily. The MDS-UPDRSIII, MMSE, and MoCA scores at three-month and one-year visits were 35/132, 22, 23, and 30/132, 23, 25, respectively, indicating mild motor impairment and mild cognitive impairment. CTT was not performed during this period, and not since then. As of today, 13 months after the treatment, the patient is maintaining the improvement, with a perceived good quality of life. Along with routine medication, he is currently on Tablet Syndopa Plus (Levodopa 100 mg + Carbidopa 25 mg) along with all other routine medications. A recent CT scan conducted 18 months after the second DTMS treatment showed a normal ventricular system and brain parenchyma (Figure *3*).



FIGURE 3: CT scan images showing normal lateral ventricles.

Discussion

Non-invasive neuromodulation in the form of DTMS could possibly be a better treatment option in iNPH. The customized DTMS treatment was found to lower the burden of recurrent LPs, simultaneously giving a positive clinical outcome. The standard DTMS protocol for Parkinson's disease was initially employed to target the gait and dyskinesia [16,17]. However, as the patient showed minimal improvement, the customized protocol became a viable approach, matching the treatment frequencies to the individualized frequencies measured in the patient. Measuring cortical activity by FFT is a routine practice applied to study the neuronal functions [19]. The same approach was applied to this patient and further extended to develop a personalized treatment protocol. The treatment regimen involved three stimulations: one over the bilateral motor cortex to reduce rigidity and improve gait, one over the medial areas of the motor cortex to target bladder incontinence, and one over the bilateral PFC to target cognitive symptoms. iNPH is characterized by inadequate absorption of CSF and consequent dilatation of the ventricular system to maintain an isobaric environment [1,2]. DTMS applied at very high stimulator output can affect the integrity of the blood-brain barrier via a glutamate-mediated mechanism [20]. A similar mechanism may have played a role in this patient by improving CSF absorption into the venous system. To our knowledge, no previously reported studies have applied DTMS in patients with iNPH.

Conclusions

DTMS using H4 coil primarily, supported by H7 coil, has helped an old male patient with iNPH recover from his symptoms without the need for VPS surgery or recurrent LPs. The first set of maintenance sessions was given after about one year of the initial cycle. The use of this unique customized protocol in this patient with iNPH is promising but requires replication in further studies to establish a standardized DTMS treatment regimen.

Appendices

Copyright and Permissions: Permission to use MDS-UPDRS has been acquired [Figure *4*]. To the best of our knowledge, HDRS is available in the public domain and no permission is required [Figure *5*]. As MMSE is copyright protected, we initiated the purchase of the MMSE forms and submission proofs are attached [Figures *7*,8]. For MoCA, the email communication is attached [Figure *9*,10].

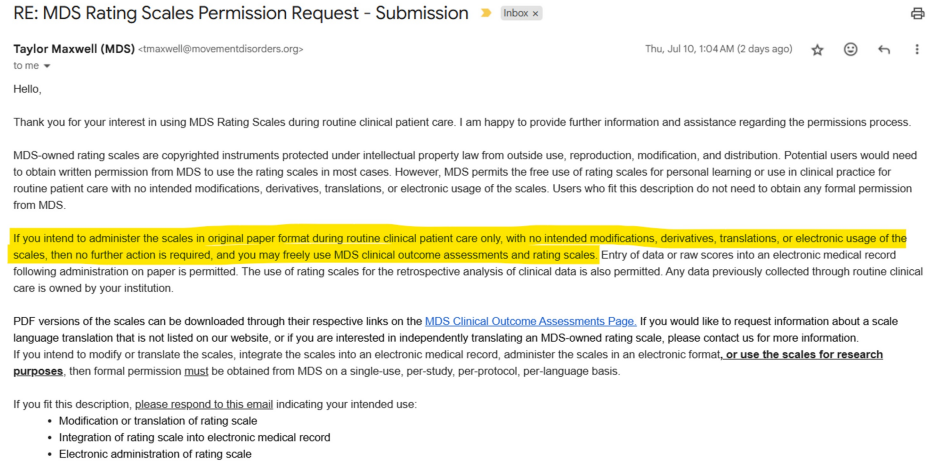

RE: MDS Rating Scales Permission Request - Submission Inbox ×

Taylor Maxwell (MDS) <tmaxwell@movementdisorders.org> Thu, Jul 10, 1:04 AM (2 days ago)
to me

Hello,

Thank you for your interest in using MDS Rating Scales during routine clinical patient care. I am happy to provide further information and assistance regarding the permissions process.

MDS-owned rating scales are copyrighted instruments protected under intellectual property law from outside use, reproduction, modification, and distribution. Potential users would need to obtain written permission from MDS to use the rating scales in most cases. However, MDS permits the free use of rating scales for personal learning or use in clinical practice for routine patient care with no intended modifications, derivatives, translations, or electronic usage of the scales. Users who fit this description do not need to obtain any formal permission from MDS.

If you intend to administer the scales in original paper format during routine clinical patient care only, with no intended modifications, derivatives, translations, or electronic usage of the scales, then no further action is required, and you may freely use MDS clinical outcome assessments and rating scales. Entry of data or raw scores into an electronic medical record following administration on paper is permitted. The use of rating scales for the retrospective analysis of clinical data is also permitted. Any data previously collected through routine clinical care is owned by your institution.

PDF versions of the scales can be downloaded through their respective links on the MDS Clinical Outcome Assessments Page. If you would like to request information about a scale language translation that is not listed on our website, or if you are interested in independently translating an MDS-owned rating scale, please contact us for more information.
If you intend to modify or translate the scales, integrate the scales into an electronic medical record, administer the scales in an electronic format, **or use the scales for research purposes**, then formal permission must be obtained from MDS on a single-use, per-study, per-protocol, per-language basis.

If you fit this description, please respond to this email indicating your intended use:

- Modification or translation of rating scale
- Integration of rating scale into electronic medical record
- Electronic administration of rating scale

FIGURE 4: Figure 4: Screenshot of the permission e-mail to use MDS-UPDRS

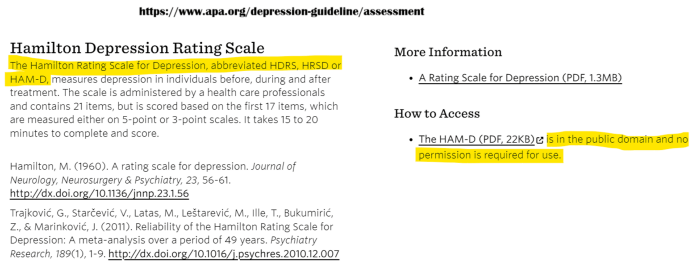

https://www.apa.org/depression-guideline/assessment

Hamilton Depression Rating Scale

The Hamilton Rating Scale for Depression, abbreviated HDRS, HRSD or HAM-D, measures depression in individuals before, during and after treatment. The scale is administered by a health care professionals and contains 21 items, but is scored based on the first 17 items, which are measured either on 5-point or 3-point scales. It takes 15 to 20 minutes to complete and score.

Hamilton, M. (1960). A rating scale for depression. *Journal of Neurology, Neurosurgery & Psychiatry, 23*, 56-61. http://dx.doi.org/10.1136/jnnp.23.1.56

Trajković, G., Starčević, V., Latas, M., Leštarević, M., Ille, T., Bukumirić, Z., & Marinković, J. (2011). Reliability of the Hamilton Rating Scale for Depression: A meta-analysis over a period of 49 years. *Psychiatry Research, 189*(1), 1-9. http://dx.doi.org/10.1016/j.psychres.2010.12.007

More Information

- A Rating Scale for Depression (PDF, 1.3MB)

How to Access

- The HAM-D (PDF, 22KB) is in the public domain and no permission is required for use.

FIGURE 5: Figure 5: Screenshot highlighting that HDRS is in public domain

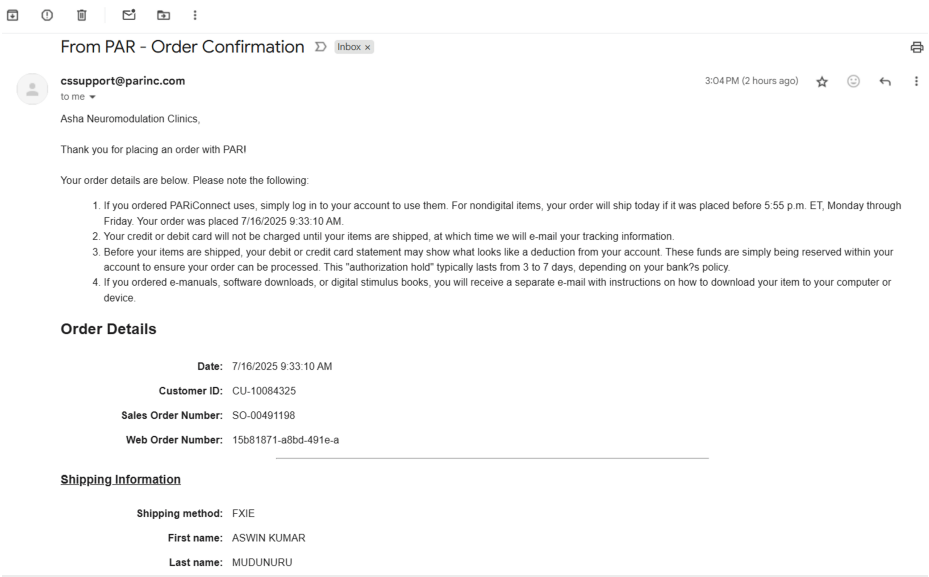

From PAR - Order Confirmation Inbox ×

cssupport@parinc.com 3:04 PM (2 hours ago)
to me

Asha Neuromodulation Clinics,

Thank you for placing an order with PAR!

Your order details are below. Please note the following:

1. If you ordered PARiConnect uses, simply log in to your account to use them. For nondigital items, your order will ship today if it was placed before 5:55 p.m. ET, Monday through Friday. Your order was placed 7/16/2025 9:33:10 AM.
2. Your credit or debit card will not be charged until your items are shipped, at which time we will e-mail your tracking information.
3. Before your items are shipped, your debit or credit card statement may show what looks like a deduction from your account. These funds are simply being reserved within your account to ensure your order can be processed. This "authorization hold" typically lasts from 3 to 7 days, depending on your bank?s policy.
4. If you ordered e-manuals, software downloads, or digital stimulus books, you will receive a separate e-mail with instructions on how to download your item to your computer or device.

Order Details

Date: 7/16/2025 9:33:10 AM
Customer ID: CU-10084325
Sales Order Number: SO-00491198
Web Order Number: 15b81871-a8bd-491e-a

Shipping Information

Shipping method: FXIE
First name: ASWIN KUMAR
Last name: MUDUNURU

FIGURE 6: Page 1 of purchase order has been initiated with PAR for the usage of MMSE

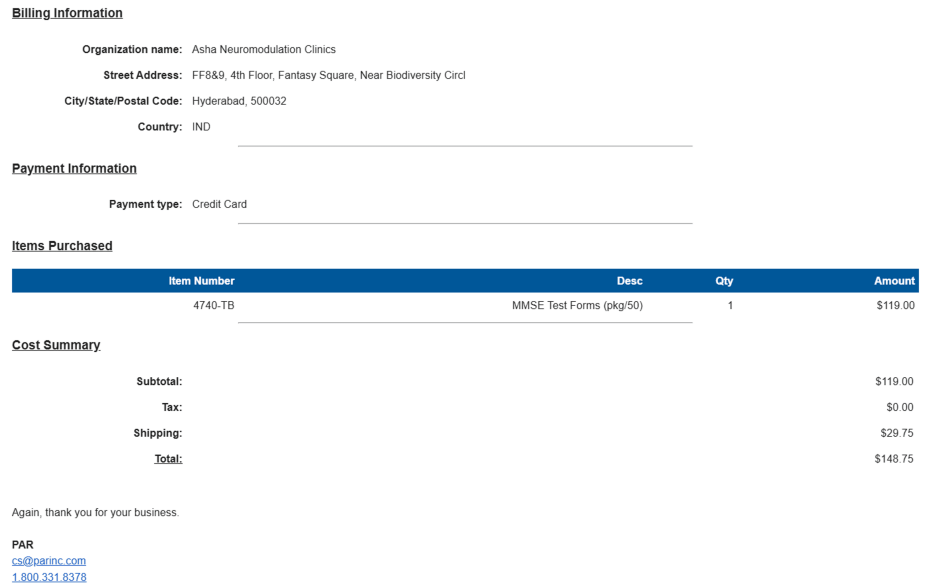

Billing Information

Organization name: Asha Neuromodulation Clinics
Street Address: FF8&9, 4th Floor, Fantasy Square, Near Biodiversity Circl
City/State/Postal Code: Hyderabad, 500032
Country: IND

Payment Information

Payment type: Credit Card

Items Purchased

Item Number	Desc	Qty	Amount
4740-TB	MMSE Test Forms (pkg/50)	1	$119.00

Cost Summary

Subtotal: $119.00
Tax: $0.00
Shipping: $29.75
Total: $148.75

Again, thank you for your business.

PAR
cs@parinc.com
1.800.331.8378

FIGURE 7: Page 2 of purchase order that has been initiated with PAR for the usage of MMSE

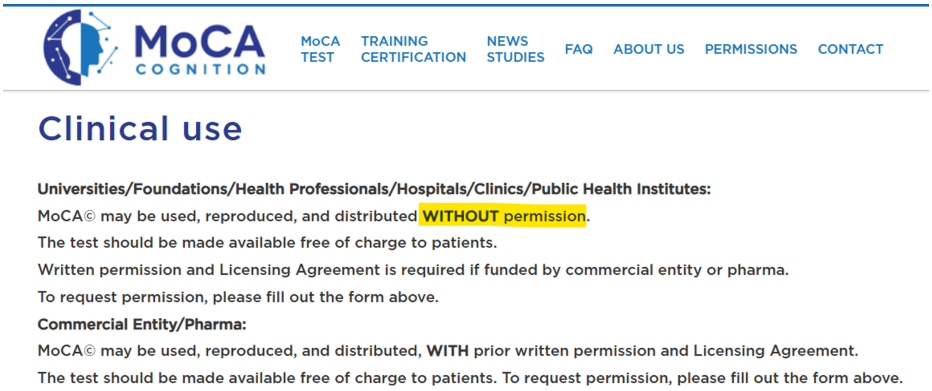

FIGURE 8: Screenshot showing that MoCA can be used without permission for clinical use



FIGURE 9: Screenshot showing e-mail communication with MoCA team for use in case report

Additional Information

Author Contributions

All authors have reviewed the final version to be published and agreed to be accountable for all aspects of the work.

Concept and design: Aswin Kumar Mudunuru, Kartik Valipay, M. S. Reddy

Acquisition, analysis, or interpretation of data: Aswin Kumar Mudunuru, Arifa Rahman, Sailaja Bomma, Lalitha V. Jahnavi

Drafting of the manuscript: Aswin Kumar Mudunuru, Kartik Valipay, Arifa Rahman, Sailaja Bomma, Lalitha V. Jahnavi

Supervision: Aswin Kumar Mudunuru, M. S. Reddy

Critical review of the manuscript for important intellectual content: M. S. Reddy

Disclosures

Human subjects: Informed consent for treatment and open access publication was obtained or waived by all participants in this study. **Conflicts of interest:** In compliance with the ICMJE uniform disclosure form, all authors declare the following: **Payment/services info:** All authors have declared that no financial support was received from any organization for the submitted work. **Financial relationships:** All authors have declared that they have no financial relationships at present or within the previous three years with any organizations that might have an interest in the submitted work. **Other relationships:** All authors have

declared that there are no other relationships or activities that could appear to have influenced the submitted work.

References

1. Bird TD, Miller BL: Alzheimer's Disease and Other Dementias. Harrison's Principles of Internal Medicine, 16th edn. Kasper DL, Braunwald E (ed): McGraw-Hill, 2005. 2:2403-4.
2. Skalický P, Mládek A, Vlasák A, De Lacy P, Beneš V, Bradáč O: Normal pressure hydrocephalus—an overview of pathophysiological mechanisms and diagnostic procedures. Neurosurg Rev. 2020, 43:1451-64. 10.1007/s10143-019-01201-5
3. Vanneste JA: Diagnosis and management of normal-pressure hydrocephalus . J Neurol. 2000, 247:5-14. 10.1007/s004150050003
4. Virhammar J, Cesarini KG, Laurell K: The CSF tap test in normal pressure hydrocephalus: evaluation time, reliability and the influence of pain. Eur J Neurol. 2012, 19:271-6. 10.1111/j.1468-1331.2011.03486
5. Nakajima M, Yamada S, Miyajima M, et al.: Guidelines for Management of Idiopathic Normal Pressure Hydrocephalus (Third Edition): Endorsed by the Japanese Society of Normal Pressure Hydrocephalus. Neurol Med Chir (Tokyo). 2021, 61:63-97. 10.2176/nmc.st.2020-0292
6. Mori E, Ishikawa M, Kato T, et al.: Guidelines for management of idiopathic normal pressure hydrocephalus: second edition. Neurol Med Chir (Tokyo). 2012, 52:775-809. 10.2176/nmc.52.775
7. Yamada S, Ishikawa M, Nakajima M, Nozaki K: Reconsidering ventriculoperitoneal shunt surgery and postoperative shunt valve pressure adjustment: our approaches learned from past challenges and failures. Front Neurol. 2021, 12:798488. 10.3389/fneur.2021.798488
8. Governale LS, Fein N, Logsdon J, Black PM: Techniques and complications of external lumbar drainage for normal pressure hydrocephalus. Neurosurgery. 2008, 63:379-84; discussion 384. 10.1227/01.NEU.0000327023.18220.88
9. Schniepp R, Trabold R, Romagna A, et al.: Walking assessment after lumbar puncture in normal-pressure hydrocephalus: a delayed improvement over 3 days. J Neurosurg. 2017, 126:148-57. 10.3171/2015.12.JNS151663
10. Davidy T, Anis S, Suminski A, et al.: Tms-evoked potentials: neurophysiological biomarkers for diagnosis and prediction of response to ventriculoperitoneal shunt in normal pressure hydrocephalus. J Clin Neurosci. 2025, 136:111234. 10.1016/j.jocn.2025.111234
11. Kammammettu C, Mudunuru AK, Gunthakandla SK, Sailaja B, Ayyadevara RL, Venkata Ramana M: EEG-based 3 Hz intermittent theta burst stimulation in a middle-aged female resulted in remission from obsessive compulsive disorder. Indian J Psychol Med. 2025, 02537176251321076. 10.1177/02537176251321076
12. Goetz CG, Fahn S, Martinez-Martin P, et al.: Movement Disorder Society-sponsored revision of the Unified Parkinson's Disease Rating Scale (MDS-UPDRS): process, format, and clinimetric testing plan. Mov Disord. 2007, 22:41-7. 10.1002/mds.21198
13. Hamilton M: A rating scale for depression. J Neurol Neurosurg Psychiatry. 1960, 23:56-62. 10.1136/jnnp.23.1.56
14. Folstein MF, Folstein SE, McHugh PR: "Mini-mental state": a practical method for grading the cognitive state of patients for the clinician. J Psychiatr Res. 1975, 12:189-98.
15. Nasreddine ZS, Phillips NA, Bédirian V, et al.: The Montreal Cognitive Assessment, MoCA: a brief screening tool for mild cognitive impairment. J Am Geriatr Soc. 2005, 53:695-9. 10.1111/j.1532-5415.2005.53221.x
16. Cohen OS, Rigbi A, Yahalom G, Warman-Alaluf N, Nitsan Z, Zangen A, Hassin-Baer S: Repetitive deep TMS for Parkinson disease: a 3-month double-blind randomized sham-controlled study. J Clin Neurophysiol. 2018, 35:159-65. 10.1097/WNP.0000000000000455
17. Hanlon CA, Lench DH, Pell G, Roth Y, Zangen A, Tendler A: Bilateral deep transcranial magnetic stimulation of motor and prefrontal cortices in Parkinson's disease: a comprehensive review. Front Hum Neurosci. 2023, 17:1336027. 10.3389/fnhum.2023.1336027
18. Sinha SR, Sullivan L, Sabau D, et al.: American Clinical Neurophysiology Society guideline 1: minimum technical requirements for performing clinical electroencephalography. J Clin Neurophysiol. 2016, 33:303-7. 10.1097/WNP.0000000000000308
19. Zhang H, Zhou QQ, Chen H, et al.: The applied principles of EEG analysis methods in neuroscience and clinical neurology. Mil Med Res. 2023, 10:67. 10.1186/s40779-023-00502-7
20. Vazana U, Veksler R, Pell GS, et al.: Glutamate-mediated blood-brain barrier opening: Implications for neuroprotection and drug delivery. J Neurosci. 2016, 36:7727-39. 10.1523/JNEUROSCI.0587-16.2016