



Case Report

H-coil repetitive transcranial magnetic stimulation for treatment of temporal lobe epilepsy: A case report



R. Gersner^{a,c,1}, L. Oberman^{b,1}, M.J. Sanchez^a, N. Chiriboga^a, H.L. Kaye^a, A. Pascual-Leone^c, M. Libenson^a, Y. Roth^d, A. Zangen^d, A. Rotenberg^{a,c,*}

^a Neuromodulation Program, Division of Epilepsy and Clinical Neurophysiology, Department of Neurology, Boston Children's Hospital, Harvard Medical School, Boston, MA, United States

^b Department of Psychiatry and Human Behavior, Warren Alpert Medical School of Brown University, Providence, RI, United States

^c Berenson-Allen Center for Noninvasive Brain Stimulation, Department of Neurology, Beth Israel Deaconess Medical Center, Harvard Medical School, Boston, MA, United States

^d Department of Life Sciences, Ben-Gurion University, Beer-Sheva, Israel

ARTICLE INFO

Article history:

Received 4 February 2016

Received in revised form 29 February 2016

Accepted 4 March 2016

Available online 16 March 2016

Keywords:

Transcranial magnetic stimulation

Epilepsy

Neuromodulation

ABSTRACT

Low frequency repetitive TMS (rTMS) of a cortical seizure focus is emerging as an antiepileptic treatment. While conventional rTMS stimulators activate only superficial cortical areas, reaching deep epileptic foci, for example in temporal lobe epilepsy (TLE), is possible using specially designed H-coils. We report the results of rTMS in a young adult with pharmacoresistant bilateral TLE who underwent three courses (of 10, 15, and 30 daily sessions) of unilateral rTMS over the hemisphere from which seizures originated most often. Seizure frequency was assessed before and after each block of rTMS sessions, as was the tolerability of the procedure. Seizure frequency declined significantly, by 50 to 70% following each rTMS course. All sessions were well-tolerated.

© 2016 The Authors. Published by Elsevier Inc. This is an open access article under the CC BY-NC-ND license (<http://creativecommons.org/licenses/by-nc-nd/4.0/>).

1. Introduction

Transcranial magnetic stimulation (TMS) is a safe and well-tolerated method for noninvasive focal cortical stimulation where small intracranial electrical currents are generated by a rapidly fluctuating extracranial magnetic field [1,2]. Repetitive TMS (rTMS) stimulates the brain with a series of magnetic pulses and has an inhibitory effect on the neuronal activity when applied at a low (≤ 1 Hz) frequency [3]. Low frequency rTMS applied for 15–30 min can reduce regional cortical excitability, and when targeted to an epileptic focus, this can suppress seizures in patients with neocortical epilepsy [4,5] and interrupt ongoing seizures in status epilepticus [6,7]. However, in patients with temporal lobe epilepsy (TLE), rTMS has failed to achieve reliable therapeutic effects [8], presumably because of its inability to reach a deep-seated seizure focus.

Recently, a special H-coil version was developed to target deep areas of the temporal lobe. Deeper and larger volumes of stimulation can be induced by the unique shape of H-coils containing an array of elements which are contoured to the shape of the skull [9]. The H-coil has been

successfully evaluated in terms of safety and efficacy of extratemporal cortical stimulation, is Food and Drug Administration (FDA)-approved for treatment of major depression [10–12], and is undergoing active evaluation in other disease states [13–16]. In the current study, we employed a system, previously tested in a saline phantom model, but not applied clinically, which we specifically adapted for mesotemporal lobe stimulation as an effort to test the safety and efficacy of 1-Hz rTMS in TLE.

Here, we describe a patient with pharmacologically intractable bilateral TLE whose seizures improved after H-coil rTMS. Case details are below.

2. Case report

A 25-year-old woman, cared for at Boston Children's Hospital, presented with initial seizure onset at age 14 years. Her most frequent seizure semiology was characterized by behavioral arrest and staring episodes, occurring initially approximately four times per week, with each seizure lasting 20–30 s. Each seizure was accompanied by a subjective sensation of lost time or confusion. While amnesic for content of individual seizures, the patient was aware that a seizure had occurred and maintained a careful seizure diary. Her ability to identify her own seizures after the fact was confirmed by her family members and periodic video-EEG monitoring during which these seizures were confirmed as epileptic. At the time of her visit, the frequency had since increased to multiple daily seizures. On EEG, she had bilateral independent seizure onsets from the left and right temporal regions. Her seizures persisted

Abbreviations: EEG, electroencephalogram; FDA, Food and Drug Administration; MMSE, Mini-mental State Exam; MRI, magnetic resonance imaging; MT, motor threshold; rMT, resting MT; TLE, temporal lobe epilepsy; TMS, transcranial magnetic stimulation; rTMS, repetitive TMS.

* Corresponding author at: 300 Longwood Ave, Fegan 9, Department of Neurology, Boston Children's Hospital, Boston, MA 02115, United States. Tel.: +1 617 919 2763; fax: +1 617 730 0463.

E-mail address: alexander.rotenberg@childrens.harvard.edu (A. Rotenberg).

¹ Contributed equally to this study.

despite adequate dosing of lamotrigine, levetiracetam, valproate, carbamazepine, and oxcarbazepine.

The patient's workup also included a normal physical exam, normal brain MRI, and EEG which showed interictal spikes in the bilateral temporal regions, and seizures originating as left or right temporal sharply contoured theta slowing progressing to spike and wave in the temporal region of origin before either termination or secondary generalization. Her past medical history was otherwise unremarkable with normal development from birth and normal IQ.

3. Materials and methods

3.1. Timeline

Written informed consent was obtained before recruitment into the trial at Boston Children's Hospital (Boston, MA). During the initial pre-treatment phase (baseline, 28 days prior to initiation of rTMS) and following the treatment process (follow-up, 28 days following rTMS), the patient was asked to keep a seizure diary in which she was instructed to record each seizure she experienced. Following each treatment session, safety and tolerability questionnaires were completed by the participant, and the Mini-mental State Examination (MMSE) was administered.

The patient underwent three H-coil rTMS treatment courses between 2013 and 2015. The stimulating coil operates in either sham or verum mode, and for the first course of daily H-coil rTMS, the subject was blinded to the condition. Stimulation for the first course consisted of ten individual sessions. The patient was unblinded as to the condition for the second and third rTMS courses, where active stimulation was delivered for 15 and 30 sessions, respectively.

3.2. Treatment

As seizures arose more often from the right temporal lobe than from the left, the right side was chosen as the therapeutic focus. During each 30-minute daily session, 1800 pulses were applied at 1 Hz using the H12-coil (Brainsway Inc., Jerusalem, Israel; Fig. 1) which was specifically designed for this study with the focus of stimulation over the right temporal region (Fig. 1). The coil was embedded in a helmet that was positioned over the patient's scalp as previously described for the H-coil system [10,12]. While the precise anatomy of the stimulated region is not known, an approximation is that, at 120% of the patient's resting motor threshold (rMT), neural activation is induced mainly over the right temporal lobe, where the field intensity is maximal, and also in prefrontal and parietal regions. Stimulation of the extra-temporal regions is required to induce the broad and deep stimulation with an H-coil.

The patient's rMT, the lowest intensity of stimulation required to elicit a motor response of the finger flexors in 5 out of 10 consecutive trials, was determined by visual inspection of the hand during stimulation. For rMT measures, the coil was tilted such that the stimulating components were displaced rostrally from the temporal region toward the centroparietal area. Once rMT was obtained, the coil was tilted to the prime position with the active portion of the electromagnet over the right temporal region. rTMS was delivered at maximal-tolerated intensities (83%–110% rMT, see Results).

3.3. Patient assessment

At each rTMS session, the patient completed a side effects questionnaire. Specifically, presence and severity of headache, neck pain, and scalp pain/irritation were assessed before and after each rTMS session. In addition, after each rTMS session, the patient reported whether she had trouble hearing, thinking, or concentrating, or had changes in mood, or had any other subjective symptoms compared to before the start of the session.



Fig. 1. Schematic of right hemisphere H12 coil in prime position. Note the relatively broad distribution of the stimulating elements over the right hemisphere.

3.4. Data analysis

The subject maintained a seizure diary and recorded seizures digitally using Seizure Tracker online software (www.seizuretracker.com). All reported seizures were classified as either isolated seizures or seizure clusters. For purposes of analysis, a seizure cluster was defined by a group of seizures with no more than 15 min between each individual seizure. In these instances, the patient was aware that greater than one seizure had occurred but was amnesic for the precise number. Thus, we counted both the standalone seizures and seizure clusters. Results are presented as means \pm SEM. Mann–Whitney U test was used to analyze changes in seizure frequency following each rTMS course and to analyze the relapse during follow-up.

4. Results

4.1. Tolerability

Given that the only other FDA-approved H-coil protocol – for prefrontal cortex stimulation – suggests stimulating at 120% rMT, we intended to gradually increase stimulation intensity to 120% of rMT in our patient. However, the stimulation intensity was less than 120% rMT. During the patient's first rTMS course, while rMT was 59% of machine output (MO), stimulation at intensity $>$ 49% MO (83% rMT) caused

discomfort. Similarly, during the second and third rTMS courses, though tolerability increased, stimulation intensity was limited by patient discomfort and reached 56% MO (100% rMT) in course 2 and 74% MO (110% rMT) in course 3. The patient's maximal tolerable stimulation intensity did not reach 120% rMT because of pain and discomfort in the right jaw and face region.

4.2. Adverse events

The patient otherwise tolerated daily H-coil rTMS sessions well with few minor adverse events. More specifically, she reported headache (following 4 out of total 55 daily sessions), neck pain (8 of 55), anxiety (1 of 55), and mild scalp irritation (1 of 55). The anxiety and mild scalp

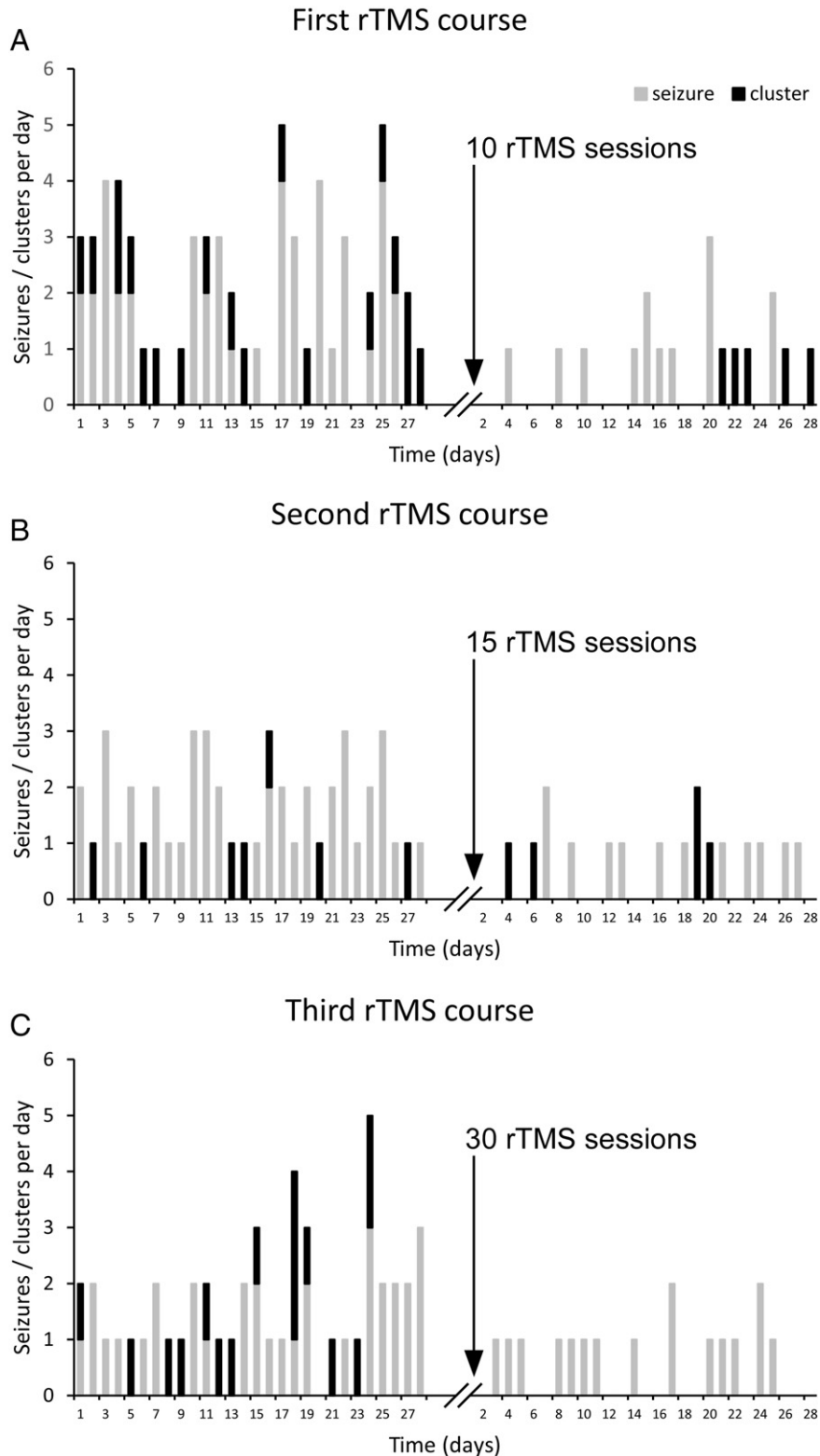


Fig. 2. Daily seizure count before and after rTMS. Number of single seizures and seizure clusters (gray and black parts of stacked columns, accordingly) before and after first (A), second (B), and third (C) rTMS courses. Black arrow marks the treatment block with associated number of sessions.

irritation occurred during the patient's first 2 visits. Each adverse event resolved spontaneously and was of short (minutes) duration. In addition, throughout all treatment courses, the results of her MMSE were stable and remained within normal range (28–30). The patient did not report changes in hearing, thinking, or concentrating ability; however, following 4 out of 55 daily sessions, the patient did report improved mood.

4.3. Efficacy

Single seizures, seizure clusters, and total number of seizures were recorded at baseline and follow-up in all treatment sessions (Fig. 2). Following each rTMS course, we found a 50–70% reduction of single ($p = 0.003$, $p < 0.001$, and $p = 0.013$ following first, second, and third rTMS course, accordingly) and total ($p < 0.001$ following all 3 rTMS courses) number of seizures (Fig. 3A and C, correspondingly). The number of

clusters (Fig. 3B) was reduced significantly after the first ($p < 0.001$), and clusters were absent after the third ($p < 0.001$) rTMS session (Fig. 3B).

In addition, following the first (but not second or third) rTMS course, we found a gradual relapse in the number of clusters ($p = 0.017$) and total number of seizures ($p = 0.016$) suggesting a more sustained anti-seizure effect of the second and third treatments (Fig. 2).

5. Discussion

We present a patient with pharmacoresistant TLE, in whom significant seizure reduction followed repeated H12-coil 1-Hz rTMS. Stimulation was safe and relatively well-tolerated in this patient. Previous studies using conventional figure-of-eight coils indicate that low frequency rTMS can suppress seizures originating from a superficial, neocortical focus [4,5]. However, rTMS with a figure-of-eight coil was ineffective in a trial aimed to test rTMS antiepileptic potential in TLE [8]. One possible explanation of differential outcomes may be the location of seizure focus, specifically the seizure focus depth relative to the skull surface. While affected regions in neocortical epilepsy are up to 2 cm deep from the skull, the affected regions of TLE may be considerably deeper, particularly in cases with a mesial temporal lobe seizure focus. Thus, our rationale was to test efficacy of the H-coil TMS system, which can effectively stimulate regions up to 6 cm deep beneath the skull surface [9,17]. And indeed, our study shows that H-coil stimulation might be effective in seizure suppression in some patients with TLE.

Another plausible explanation for difficulty with suppressing seizures by rTMS in TLE is the size of the epileptogenic network, which in many cases encompasses more than just the mesial temporal structures [18,19] and involves appreciable portions of the remaining temporal lobe and extratemporal structures. Here too, the H-coil, which enables not just deep but also broad stimulation that likely activates temporal as well as some extratemporal structures, may be advantageous.

In addition to documenting seizure improvement in TLE after H-coil rTMS, our study may be the first to report serial rTMS in a patient with epilepsy, in this case with progressive increases in relative intensity and duration rTMS protocols. Also in contrast to many case reports, the patient was blinded as to whether she received verum or sham rTMS during the first treatment block. We note that, although the second and third treatment courses were open label, their efficiency was not significantly different from the single-blinded first treatment block suggesting minimal placebo effect.

As we increased the duration of rTMS courses from 10 to 15 to 30 stimulation days, we observed that seizure reduction was stable: seizure frequency declined by 50–70% after each rTMS course. However, the second and third prolonged rTMS courses did correspond to longer time to relapse, suggesting either a cumulative therapeutic effect of recurrent treatment blocks or greater seizure suppression with rTMS course that contained more stimulation days/sessions. Of course, these interpretations should be taken with caution as the patient was not blinded to the treatment condition in courses 2 and 3.

While too early for a definitive analysis of efficacy, our report indicates the feasibility of using H-coil rTMS to suppress TLE seizures and underscores a future utility of a large randomized, controlled trial.

Acknowledgments

This work was funded by the Epilepsy Therapy Project and Epilepsy Foundation, and in-kind support from Brainsway Inc.

Controlled trial of 1 Hz repetitive transcranial magnetic stimulation for treatment of temporal lobe epilepsy.

Potential conflict of interest

Authors L.O., M.J.S., N.C., H.L.K., and M.L. report no financial interests or potential conflicts of interest. A.R. is a founder of and consultant to

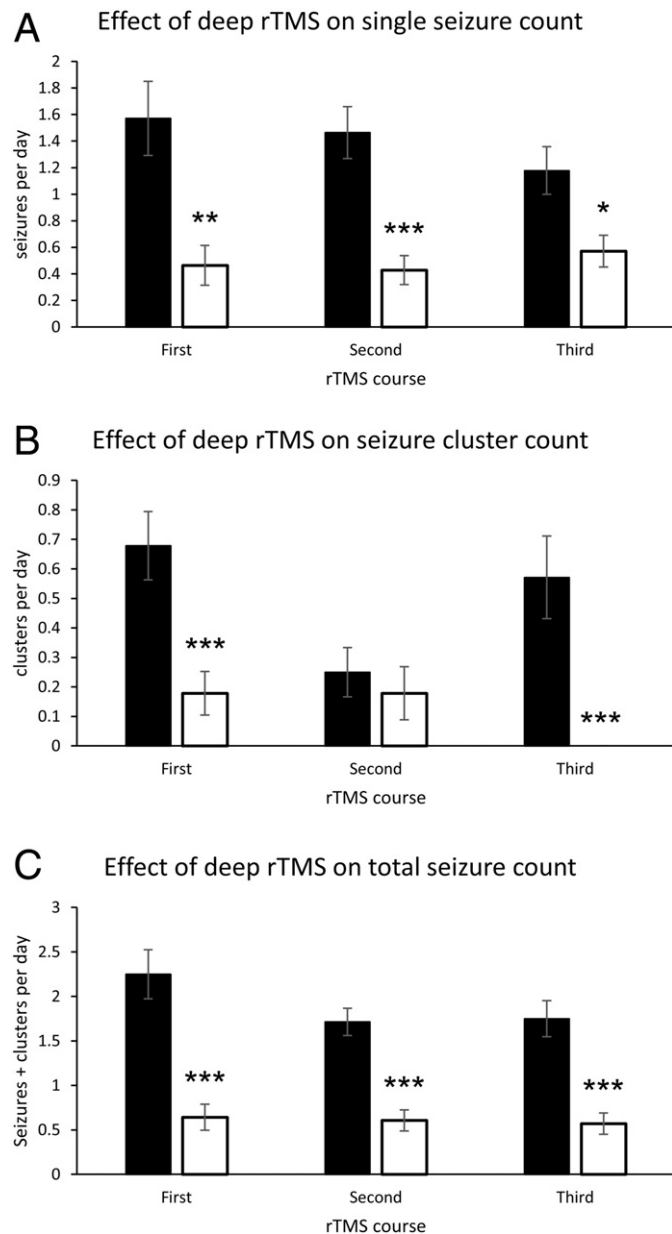


Fig. 3. The effect of H-coil rTMS on seizure count. Data are presented as mean \pm SEM of baseline (black) and follow-up (white) single seizures (A), seizures cluster (B), and total seizure count (C). Both single seizures (A) and total seizure count were reduced following all three treatment blocks. Seizure cluster (B) reduction displayed following first and third but not second treatment block. * $p < 0.05$, ** $p < 0.01$, *** $p < 0.001$ as compared to baseline.

Neuro'motion Inc. and serves on the scientific advisory board of NeuroRex Inc. A.R. receives or has recently received research support from Brainsway, Neuroelectrics, Sage Therapeutics, and Eisai. A.P.L. serves on the scientific advisory boards for Nexstim, Neuronix, Starlab Neuroscience, Neuroelectrics, and Neosync. A.R. and A.P.L. are listed as inventors on several issued and pending patents on the real-time integration of TMS with EEG and magnetic resonance imaging. R.G. has consulted to Brainsway Inc. Y.R. and A.Z. are coinventors of the deep TMS H-coil technology, serve as consultants, and have financial interests in Brainsway Inc. which produced the H-coil system.

References

- [1] Pereira LS, Müller VT, da Mota Gomez M, Rotenberg A, Fregni F. Safety of repetitive transcranial magnetic stimulation in patients with epilepsy: a systematic review. *Epilepsy Behav* 2016;57(Pt A):167–76 [Epub ahead of print].
- [2] Rossi S, Hallett M, Rossini PM, Pascual-Leone A, Safety of TMS Consensus Group. Safety, ethical considerations, and application guidelines for the use of transcranial magnetic stimulation in clinical practice and research. *Clin Neurophysiol* 2009; 120:2008–39.
- [3] Chen R, Classen J, Gerloff C, Celnik P, Wassermann EM, Hallett M, et al. Depression of motor cortex excitability by low-frequency transcranial magnetic stimulation. *Neurology* 1997;48:1398–403.
- [4] Fregni F, Otachi PT, Do Valle A, Boggio PS, Thut G, Rigonatti SP, et al. A randomized clinical trial of repetitive transcranial magnetic stimulation in patients with refractory epilepsy. *Ann Neurol* 2006;60:447–55.
- [5] Sun W, Mao W, Meng X, Wang D, Qiao L, Tao W, et al. Low-frequency repetitive transcranial magnetic stimulation for the treatment of refractory partial epilepsy: a controlled clinical study. *Epilepsia* 2012;53:1782–9.
- [6] Liu A, Pang T, Herman S, Pascual-Leone A, Rotenberg A. Transcranial magnetic stimulation for refractory focal status epilepticus in the intensive care unit. *Seizure* 2013; 22:893–6.
- [7] Rotenberg A, Bae EH, Takeoka M, Tormos JM, Schachter SC, Pascual-Leone A. Repetitive transcranial magnetic stimulation in the treatment of epilepsy partialis continua. *Epilepsy Behav* 2009;14:253–7.
- [8] Theodore WH, Hunter K, Chen R, Vega-Bermudez F, Boroojerdi B, Reeves-Tyer P, et al. Transcranial magnetic stimulation for the treatment of seizures: a controlled study. *Neurology* 2002;59:560–2.
- [9] Roth Y, Amir A, Levkovitz Y, Zangen A. Three-dimensional distribution of the electric field induced in the brain by transcranial magnetic stimulation using figure-8 and deep H-coils. *J Clin Neurophysiol* 2007;24:31–8.
- [10] Levkovitz Y, Harel EV, Roth Y, Braw Y, Most D, Katz LN, et al. Deep transcranial magnetic stimulation over the prefrontal cortex: evaluation of antidepressant and cognitive effects in depressive patients. *Brain Stimul* 2009;2:188–200.
- [11] Rosenberg O, Dinur Klein L, Gersner R, Kotler M, Zangen A, Dannon P. Long-term follow-up of MDD patients who respond to deep rTMS: a brief report. *Isr J Psychiatry Relat Sci* 2015;52:17–23.
- [12] Levkovitz Y, Isserles M, Padberg F, Lisanby SH, Bystritsky A, Xia G, et al. Efficacy and safety of deep transcranial magnetic stimulation for major depression: a prospective multicenter randomized controlled trial. *World Psychiatry* 2015;14:64–73.
- [13] Rosenberg O, Gersner R, Klein LD, Kotler M, Zangen A, Dannon P. Deep transcranial magnetic stimulation add-on for the treatment of auditory hallucinations: a double-blind study. *Ann General Psychiatry* 2012;11:13.
- [14] Harel EV, Zangen A, Roth Y, Reti I, Braw Y, Levkovitz Y. H-coil repetitive transcranial magnetic stimulation for the treatment of bipolar depression: an add-on, safety and feasibility study. *World J Biol Psychiatry* 2011;12:119–26.
- [15] Ceccanti M, Inghilleri M, Attilia ML, Raccach R, Fiore M, Zangen A, et al. Deep TMS on alcoholics: effects on cortisol levels and dopamine pathway modulation. A pilot study. *Can J Physiol Pharmacol* 2015;93:283–90.
- [16] Spagnolo F, Volonte MA, Fichera M, Chieffo R, Houdayer E, Bianco M, et al. Excitatory deep repetitive transcranial magnetic stimulation with H-coil as add-on treatment of motor symptoms in Parkinson's disease: an open label, pilot study. *Brain Stimul* 2014;7:297–300.
- [17] Zangen A, Roth Y, Voller B, Hallett M. Transcranial magnetic stimulation of deep brain regions: evidence for efficacy of the H-coil. *Clin Neurophysiol* 2005;116: 775–9.
- [18] Jin SH, Jeong W, Chung CK. Mesial temporal lobe epilepsy with hippocampal sclerosis is a network disorder with altered cortical hubs. *Epilepsia* 2015;56:772–9.
- [19] Morgan VL, Abou-Khalil B, Rogers BP. Evolution of functional connectivity of brain networks and their dynamic interaction in temporal lobe epilepsy. *Brain Connect* 2015;5:35–44.